



PATIENT

Nayla Folino

SPECIES

Canine

BREED

Beagle

SEX

Female Spayed

AGE

11 years

WEIGHT

26lbs

PRESENTING CLINICAL SIGNS

History: Grade IV/VI systolic murmur. Urinary incontinence, hematuria, passing blood clots. Renal values WNL. UA: >50 RBC/HPF; WBC 12/HPF. BP: 130, 132mmHg.
*Sedated with gabapentin, trazadone, butorphanol.

ECHOCARDIOGRAM FINDINGS

2D, m-mode, color flow and Doppler imaging is available.

Left ventricle: The LV diameter is increased with hyperdynamic function. LV wall thicknesses are normal.

Left atrium: The left atrium is moderately dilated.

Mitral valve: The mitral valve is diffusely thickened with mild prolapse into the left atrial lumen. Severe eccentric mitral regurgitation with a normal velocity.

Aortic valve/Aorta: The aortic valve is normal in morphology and mobility. Normal aortic outflow velocity; laminar flow. No aortic insufficiency.

Right ventricle: Normal right ventricular diameter and morphology indicating no overt evidence of pulmonary arterial hypertension.

Right atrium: Normal RA dimension.

Tricuspid valve: The tricuspid valve appears mildly thickened with mild tricuspid regurgitation. Normal velocity.

Pulmonic valve/Pulmonary artery: The pulmonic valve is normal in morphology and mobility. No pulmonic insufficiency. Normal RVOT velocity; laminar flow.

Pericardium/other: No pericardial or pleural effusion noted. No obvious cardiac masses.
Heart rhythm: ECG reveals a sinus rhythm with an average HR of 80bpm.

INTERPRETED BY

Maggie Machen
Lamy, DVM
DACVIM (Cardiology)

2-Dimensional Measurements

Ao diam (cm)	1.8
LA diam (cm)	3.3
LA:Ao (Swe)	1.8
IVS thickness (cm)	0.74
LVID diastole (cm)	3.8
PW thickness (cm)	0.74
LVID systole (cm)	1.8
FS (%)	52

Doppler Measurements

PV Vmax (m/s)	0.73
AoV Vmax (m/s)	1.55
MR Vmax (m/s)	5.3
TR Vmax (m/s)	2.3
TR PG (mmHg)	21

IMAGING

PERFORMED BY

Pamela Harrigan,
RDCS

HOSPITAL NAME

Pine Banks Animal
Hospital

REFERRING VET

Dr. Jabar

INVOICE

24868

DATE

6/20/22

INTERPRETATION OF THE FINDINGS

Chronic degenerative valve disease causing severe mitral and mild tricuspid regurgitation. Moderate left atrial and ventricular enlargement indicates there is relatively low risk for imminent complication, however risk for progression to spontaneous congestive heart failure in the future is elevated. No additional issues are identified.

Given LA dilation, Pimobendan is recommended as below. Assessment of progression in the future will help predict long term outcome, however prognosis is guarded at this stage (B2).

RECOMMENDATIONS

- Institute heart muscle support Pimobendan 0.3mg/kg PO q12h.
- Omega fatty acid supplementation and mild salt restriction may be of some long-term benefit.



PATIENT

Nayla Folino

- Once on Pimobendan for 3-5 days, anesthetic risk is considered mild if needed. Cardiac protective drug choices (opioid/benzodiazepine premedication, propofol or alfaxalone induction, isoflurane gas) are recommended. Pre-oxygenate for 5-10 minutes prior to induction. Monitor for arrhythmias, hypotension, and hypoxia both intra and post-operatively and intervene as necessary. Mild IV fluid restriction is recommended to avoid fluid overload. Avoid heart rate stimulating drugs such as atropine unless clinically indicated.

SPECIES

Canine

BREED

Beagle

- Monitor for development of a cough, labored breathing, exercise intolerance or collapse episodes.

PLAN

SEX

Female Spayed

- Recommend conservative monitoring with a recheck echocardiogram in 6 months, sooner if any development of clinical signs.

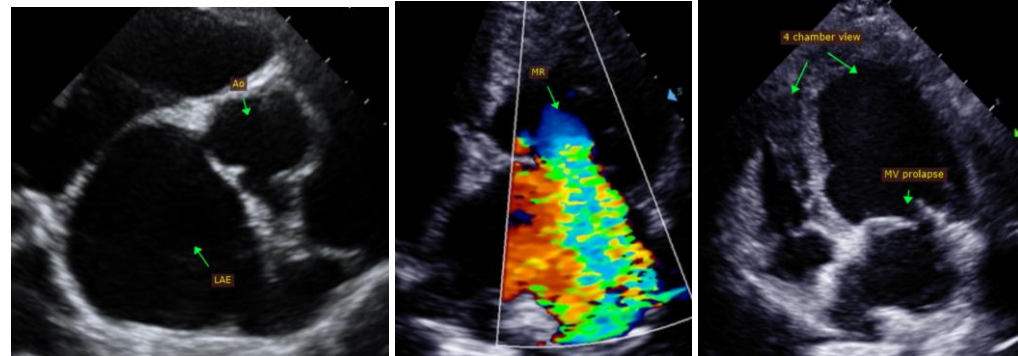
AGE

11 years

WEIGHT

26lbs

IMAGES



INTERPRETED BY

Maggie Machen
 Lamy, DVM
 DACVIM (Cardiology)

The information and recommendations provided are based on the images presented by the referring veterinarian. No evaluation can be communicated regarding pathology that was not visible in the image/video clips provided.

IMAGING PERFORMED BY

Pamela Harrigan,
 RDCS

Thank you for this referral. This report was generated using transcription software, and minor dictation errors may be present. If the clinical or image interpretation does not parallel your findings or if I can be of any further assistance, please contact me.

HOSPITAL NAME

Pine Banks Animal
 Hospital

Maggie Machen Lamy, DVM
 Diplomat of the American College of Veterinary Internal Medicine (Cardiology)
 info@sonopath.com

REFERRING VET

Dr. Jabar

INVOICE

24868

DATE

6/20/22